

ATLANTIS™ ISUS fixed implant suprastructures for optimal esthetics, function and patient satisfaction

– Even when conditions for implant placement are not ideal and the implants are placed with severe divergence

Fifty-five-year-old male patient with total tooth loss due to advanced marginal periodontitis. He was not able to use removable dentures and came to our clinic.

Fixed implant-supported bridges both in the upper and lower jaw were planned. Bone conditions were not ideal, and the implants could not be parallel. Despite this the surgeon placed 12 OsseoSpeed 3.5, 11 mm implants in a two-stage surgical procedure. After a healing period of 12 weeks, UniAbutments were placed and impressions were taken.

An ATLANTIS ISUS Bridge with angulated screw access and ceramic was fabricated for the upper jaw along with an ATLANTIS ISUS Hybrid restoration with composite for the lower jaw. Even without an optimal placement for the implants, final results showed optimal conditions for function and cleaning without compromising on the esthetics.

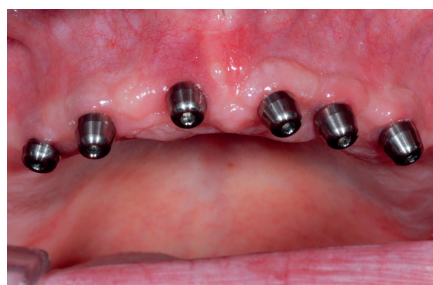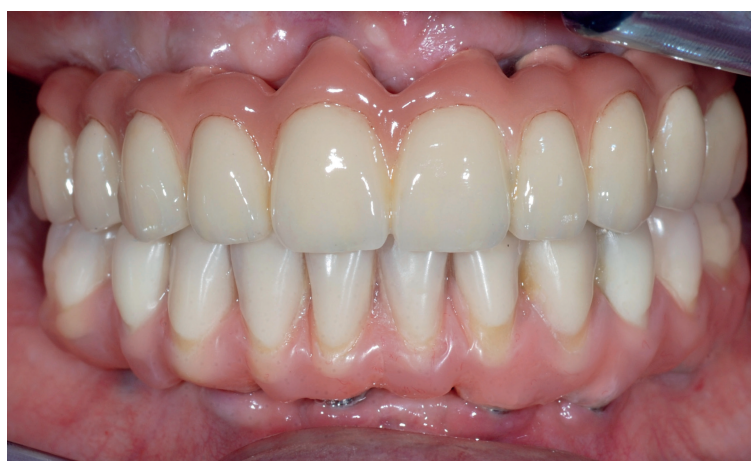Per-John Halvorsen, DDS
Licensed for implant
prosthodontics
Kristiansund, Norway



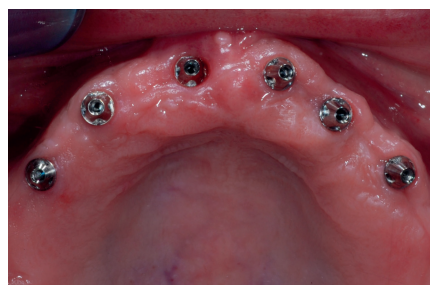Svein Thorstensen, MDT
Proteket AS
Oslo, Norway



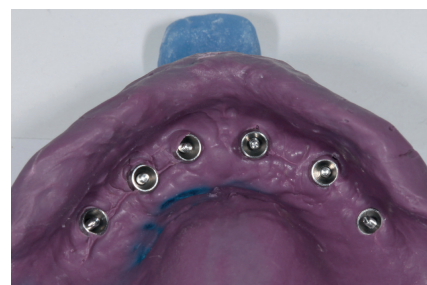*Surgical procedures was performed by Sissel Heggdalsvik, Dr. Odont.
Head of Oral and Maxillofacial Department, Molde, Norway*



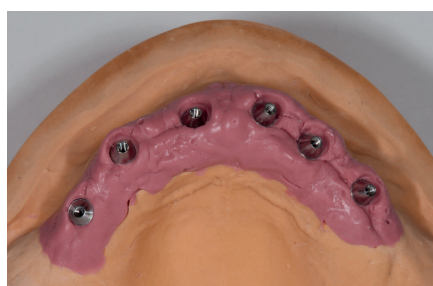
1. UniAbutments were installed and after two weeks of healing, the clinical situation shows healthy soft tissue around the healing cups.



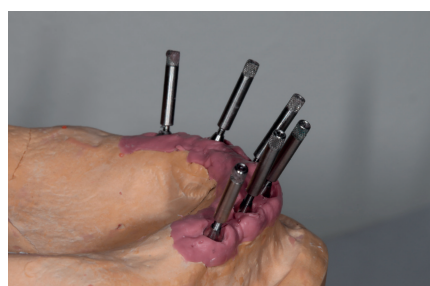2. Occlusal view of the UniAbutment. The design of the UniAbutments ensures a controlled and secure procedure when taking the impression and securing the final restoration.




3. An individual open-tray impression was taken using UniAbutment Pick-ups and polyether impression material (Impregum, 3M ESPE).



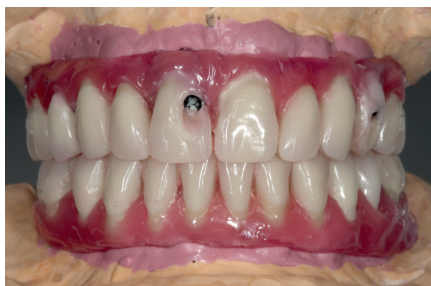4. A master model with a soft tissue mask is fabricated at the dental laboratory.



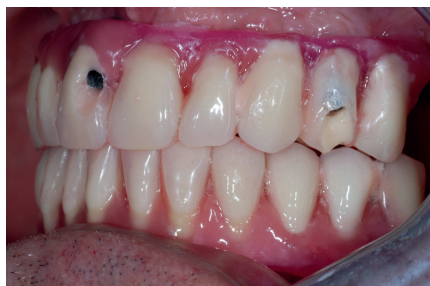5. Non-parallel implant placement requires a restorative solution that can be designed to meet optimal function and high esthetic demands.



6. Angulated screw access allows the prosthetic screw access channel to be set at an angle of up to 30 degrees off the implant/abutment axis for optimal esthetics and function.



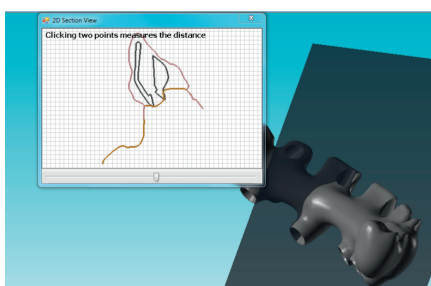
7. Teeth setup on a master model secured with 3 screws for try-in. Screw access holes in the buccal part of teeth before angulation.



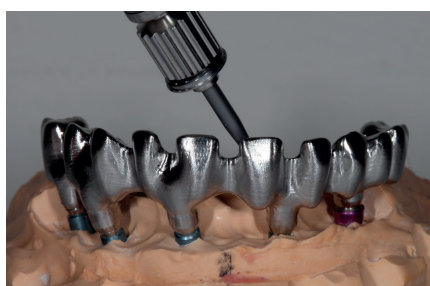8. Try-in of the teeth set-up. Screw access holes in the buccal part of teeth before angulation.



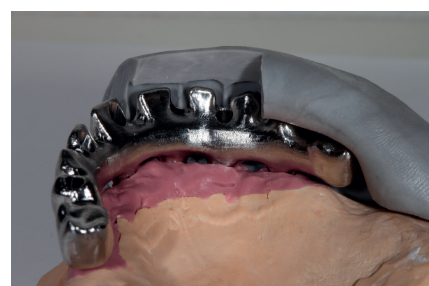9. After the implant suprastructures have been designed using the latest digital technology and ISUSsoft, the dental technician receives the file for review and approval.



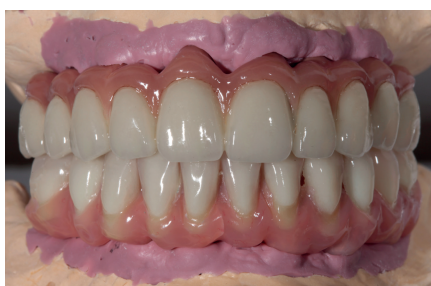10. After review and final approval of the design in the ATLANTIS ISUS Viewer, the suprastructure is milled.



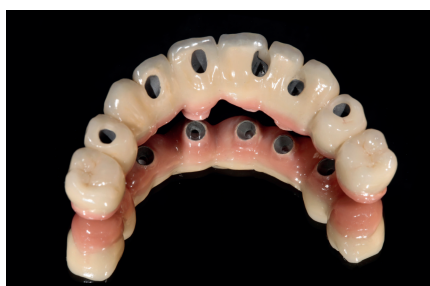11. The ATLANTIS ISUS Bridge provides a full anatomical framework for the ceramic layering technique. Designed with angulated screw access for optimal esthetic results.



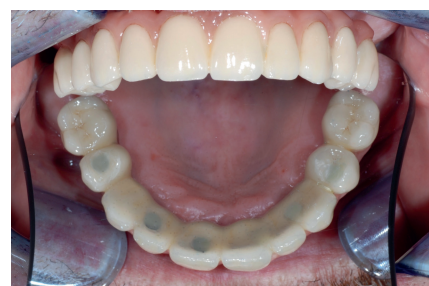12. Implant suprastructure is designed to allow for ceramic build-up.



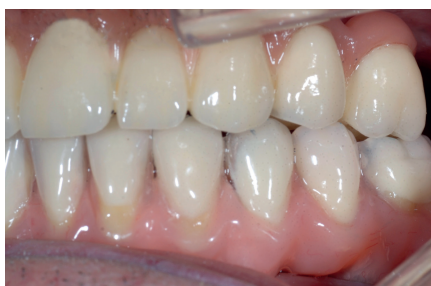13. Final restoration with the ATLANTIS ISUS Bridge using the ceramic layering technique in the upper jaw and the ATLANTIS ISUS Hybrid with composite build-up in the lower jaw.



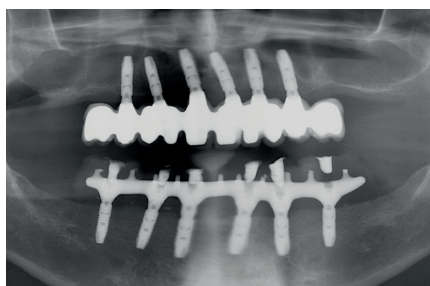
14. Despite the anterior position and divergent angulation of the implants, all screw access holes are placed in a preferable distance to the cusps and incisal edges. This minimizes the risk of porcelain fracture and ensures good esthetics.



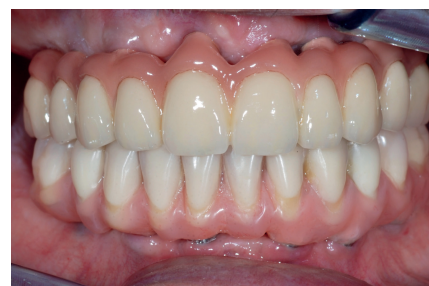15. Screw access holes are closed with composite (Filtek Supreme XTE B3D, 3M ESPE). Optimal position of the screw channel for improved function and esthetics.



16. The final implant suprastructures in place. Passive fit was verified and the patient is satisfied with the final outcome. Bilateral even occlusal contact. Lateral guidance with "group function" on canines and premolars.



17. Radiographic showing full arch ATLANTIS ISUS implant restorations in upper and lower jaws with passive fit.



18. Final restoration with the ATLANTIS ISUS Hybrid in the lower jaw for best possible function and ATLANTIS ISUS Bridge in the upper jaw for optimal esthetic results.

This case report is published as an inspiration for you as a clinician and not necessarily as a recommendation from DENTSPLY Implants.

www.dentsplyimplants.com

DENTSPLY
IMPLANTS